

Objectives

After reading this chapter, you will understand:

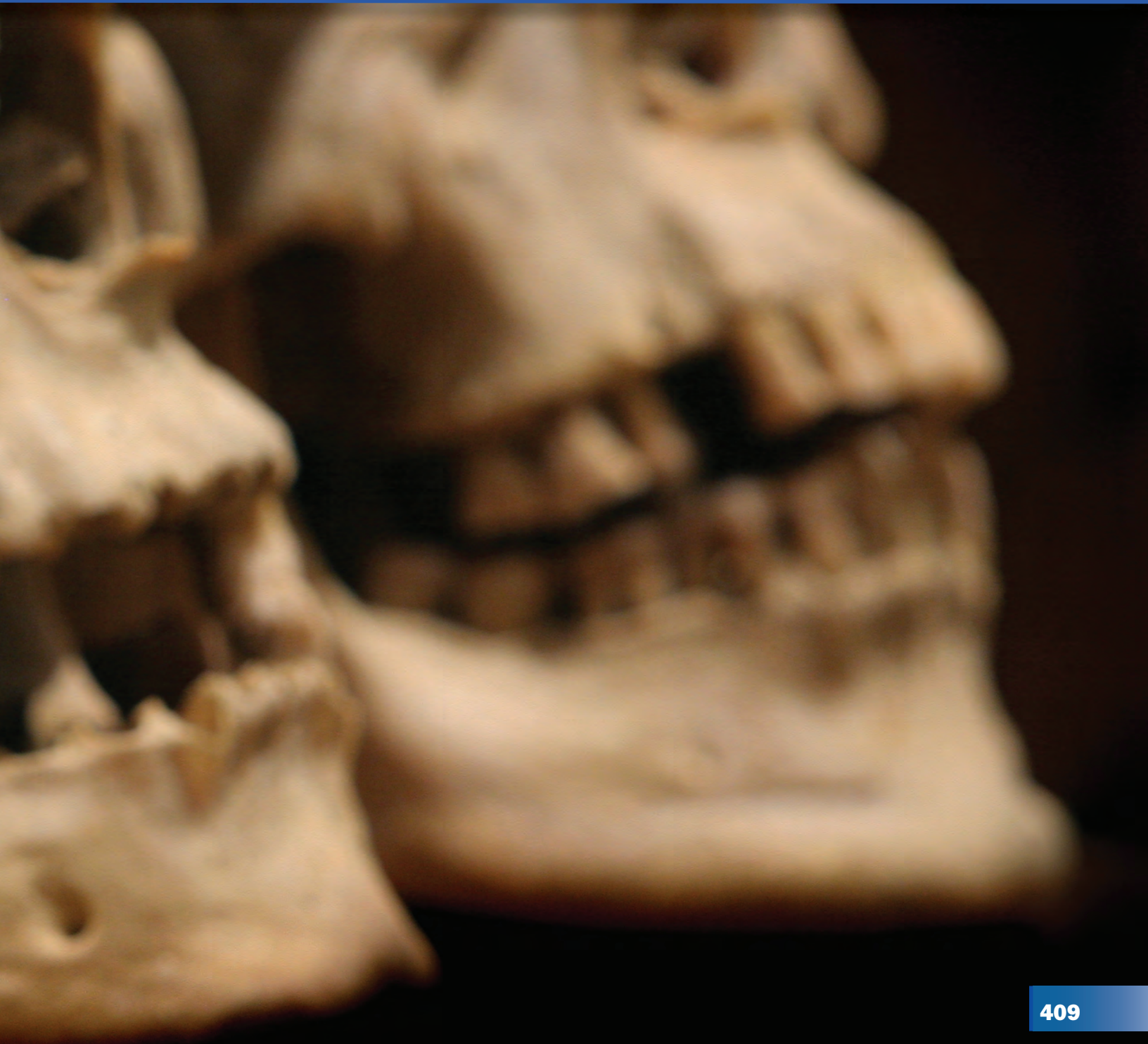- How anthropologists can use bones to determine whether remains are human; to determine the sex, age, and sometimes race of an individual; to estimate height; and to determine when the death may have occurred.

You will be able to:

- Distinguish between a male and a female skeleton.
- Give an age range after examining unknown remains.
- Describe differences in skull features among the three major racial categories.
- Estimate height by measuring long bones.
- Use technology and mathematics to improve investigations and communications.
- Identify questions and concepts that guide scientific investigations.
- Communicate and defend a scientific argument.

“There is a brief but very informative biography of an individual contained within the skeleton, if you know how to read it . . .”

—Clyde Snow, forensic anthropologist



Teacher Note

The TRCD for this chapter includes a PowerPoint presentation, which is an overview of the chapter. It can be used as introductory material or at the end as a review.

Investigating Human Remains

A double homicide was discovered in Southern California in 1981; two male bodies were found fully clothed in a field near Gorman. Both were severely decomposed, with gunshot wounds to the head and chest. The first steps in identifying the two included processing the dehydrated fingers for fingerprints and examining the skeletal structures for age.

In 1986 a badly decomposed body was recovered from the Los Angeles County sewer system. The body was partially clothed, its legs bound together with a chain. The remains had no internal pelvic organs or external features that could have been used for identification.

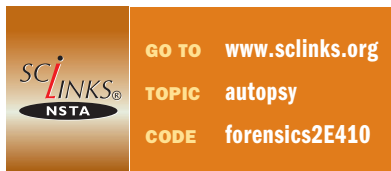A large, charred torso was recovered from the Cerritos air crash disaster site in Los Angeles County in September 1986. The remains consisted of portions of the head, trunk, and right arm. The nose and facial features were gone, although some of the teeth were still there. Neither age nor gender was obvious.

What features of the skeletal remains can officials use to identify these unknown individuals? What types of specialists do officials consult?

Forensic Anthropology: Skeletal Remains

The period of time from death to skeletal remains is of interest to the pathologist initially, and then to the forensic entomologist, as you learned in Chapter 13. What is finally left falls in the domain of the forensic anthropologist. Anthropology is the study of humankind including anatomy, variability, evolution, and culture. **Forensic anthropology** is a type of applied physical anthropology that specializes in the human skeletal system and its changes and variations, for purposes of legal inquiry and ultimately for presentation in courts of law. A forensic anthropologist can use knowledge of the skeletal system to identify crime victims and sometimes to determine the cause or circumstances of death. The forensic anthropologist can apply information learned from modern forensic cases to the study of skeletons that are hundreds or even thousands of years old.

forensic anthropology: a type of applied physical anthropology that specializes in the human skeletal system for purposes of identifying unknown remains



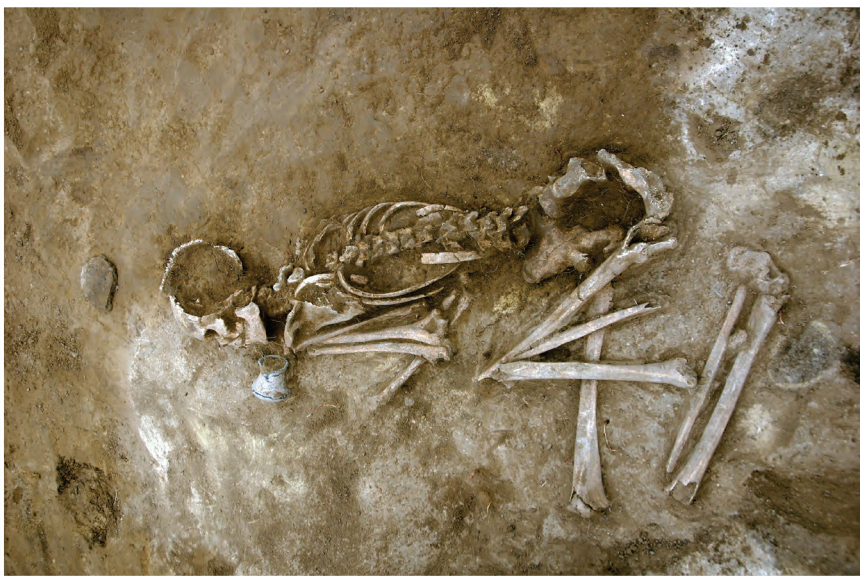

Anthropologists on an archeological dig

decomposed, were badly burned, or have become mummified or skeletonized. Information gathered from skeletal features is the principal source of information about an unidentified individual. Forensic anthropologists may be asked to search an area for remains and help in recovering them.

Using forensics, the investigator can often answer many questions:

- Are the remains human?
- Are the remains of a single individual or mixed remains of several individuals?



Human remains

- When did the death occur?
- Was the body disturbed after death?
- What are the gender, age, and race of the individual?
- What caused the death?
- What kind of death was it—a homicide, a suicide, an accident or natural death, or is the cause still undetermined?
- Did the individual have any anatomical peculiarities, signs of disease, or old injuries?
- Can the individual's height, body weight, and physique be estimated?
- Can facial features be reconstructed?

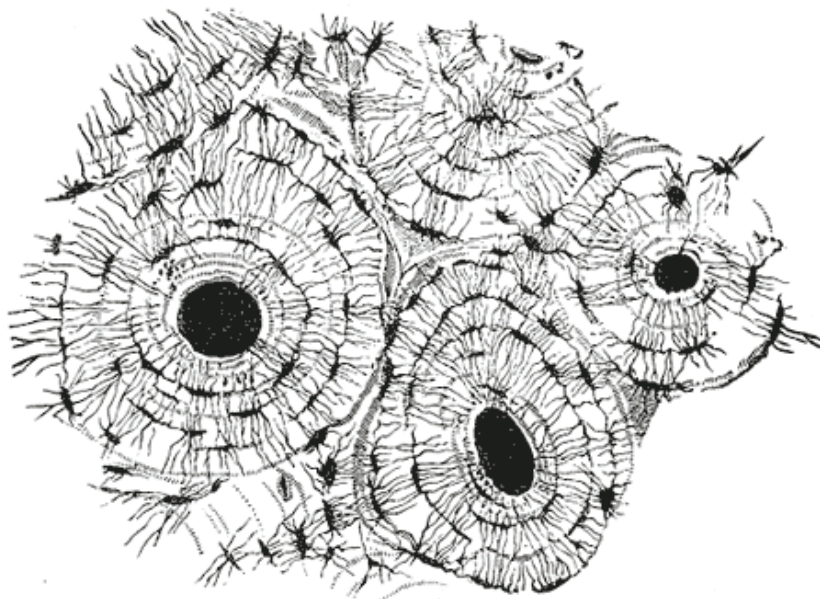
Human versus Animal Bones

The study of bones is known as **osteology**. Humans and animals have different skeletal structures, different bones, and differently shaped bones.

osteology: the study of bones

osteons: structures in bones that carry the blood supply

An expert in anatomy or osteology can tell the difference by visual inspection. Sometimes it is difficult to tell the difference in smaller bones or when only a small portion of the bone is available, but human bone can be distinguished from animal bone through microscopic examination of the cellular structures. Bones have holes or **osteons** in them to carry their blood supply. Microscopic examination shows that in animals the osteons form a regular pattern, but in humans the osteons are arranged in a more chaotic pattern.



Sketch of human bone showing osteons

The Skeleton

An adult human has 206 bones. In younger humans, bones vary in number with age as the bones develop and grow. Ossification sites (where growth takes place) are found on many bones. Most bones of the body have a similar structural pattern.

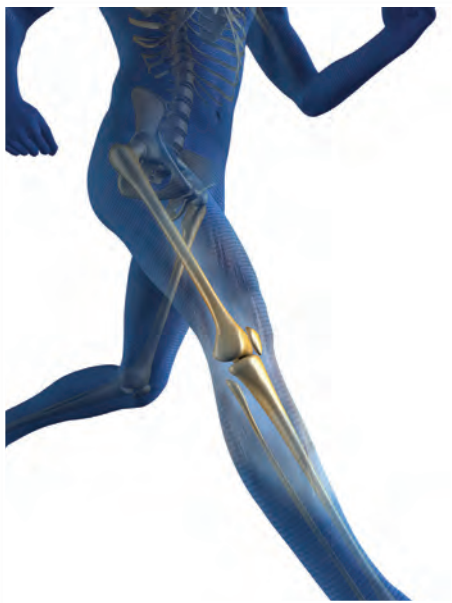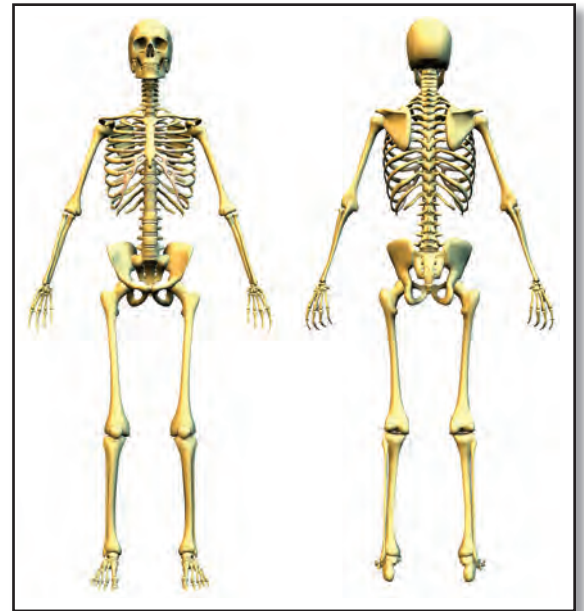
The skeleton performs many vital functions. It provides structure and rigidity for the body. It shelters and protects soft tissue and internal organs. The skull surrounds and protects the brain; the sternum and rib cage encase the heart and lungs. The skeleton provides sites for the attachment of the muscles, tendons, and ligaments that allow the body to move. The skeleton stores minerals and houses sites that produce red blood cells.

The body moves through the interaction of muscles and the skeleton. Tendons and ligaments are structurally similar but function differently. Muscles are connected to the bones by tendons. Bones are connected to each other or to joints with ligaments. Joints are points where a muscle is connected to two different bones and contracts to pull them together.

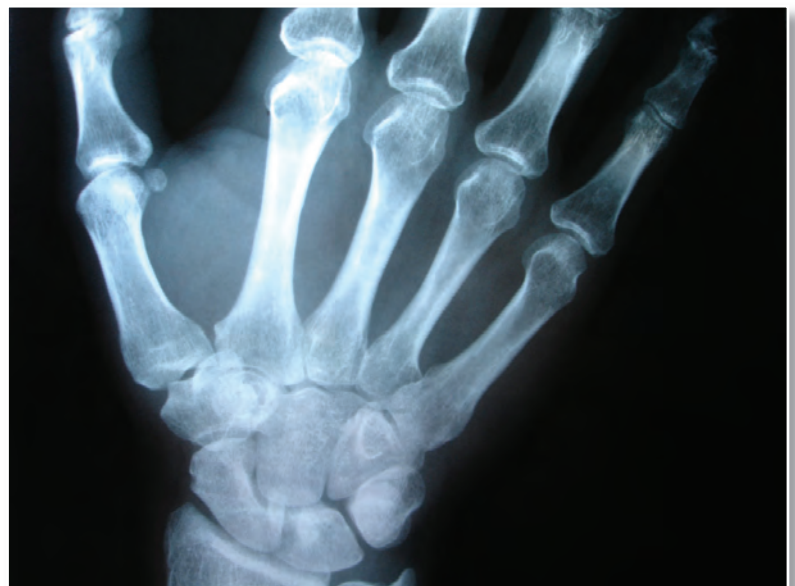The marrow located in some bones produces blood cells. An average of 2.6 million red blood cells are

Teacher Note

It is very helpful to have a skeleton in the front of the class to refer to throughout this unit. Students are very curious about the human skeleton. See if your biology teacher has access to one.



Bones in a man running



X ray of human hand; note the short, square bones in the wrist

produced each second by the bone marrow to replace those worn out and destroyed by the liver. The marrow also produces the cells of the immune system.

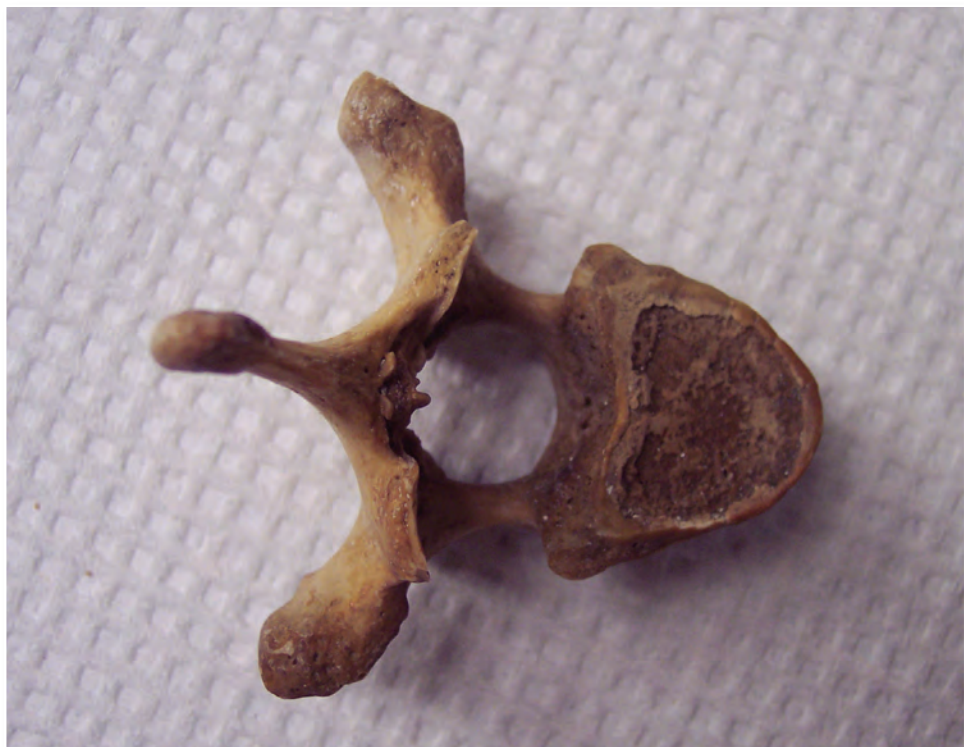

GO TO www.scilinks.org
TOPIC skeletal system
CODE forensics2E414

Bones serve as a storage area for minerals such as calcium and phosphate. When an excess of these minerals is present in the blood, buildup will occur within the bones. When the supply of these minerals within the blood is low, they are withdrawn from the bones to replenish that supply. Bone tissue can also clean the body by removing heavy metals and other foreign elements from the blood. It stores them and releases them slowly for excretion, lessening any ill effects on nervous tissue.

Bones can be classified as long, short, flat, or irregular:

- The long bones are longer than they are wide; they include bones in the arms, legs, hands, and feet.
- The short bones are approximately as long as they are wide; they are found in the wrist and ankle.
- The flat bones are flat and enclose soft organs; they include most bones in the skull and the scapula, sternum, hip bone, and ribs.
- The irregular bones are irregularly shaped; they include the vertebrae and some of the bones in the skull.

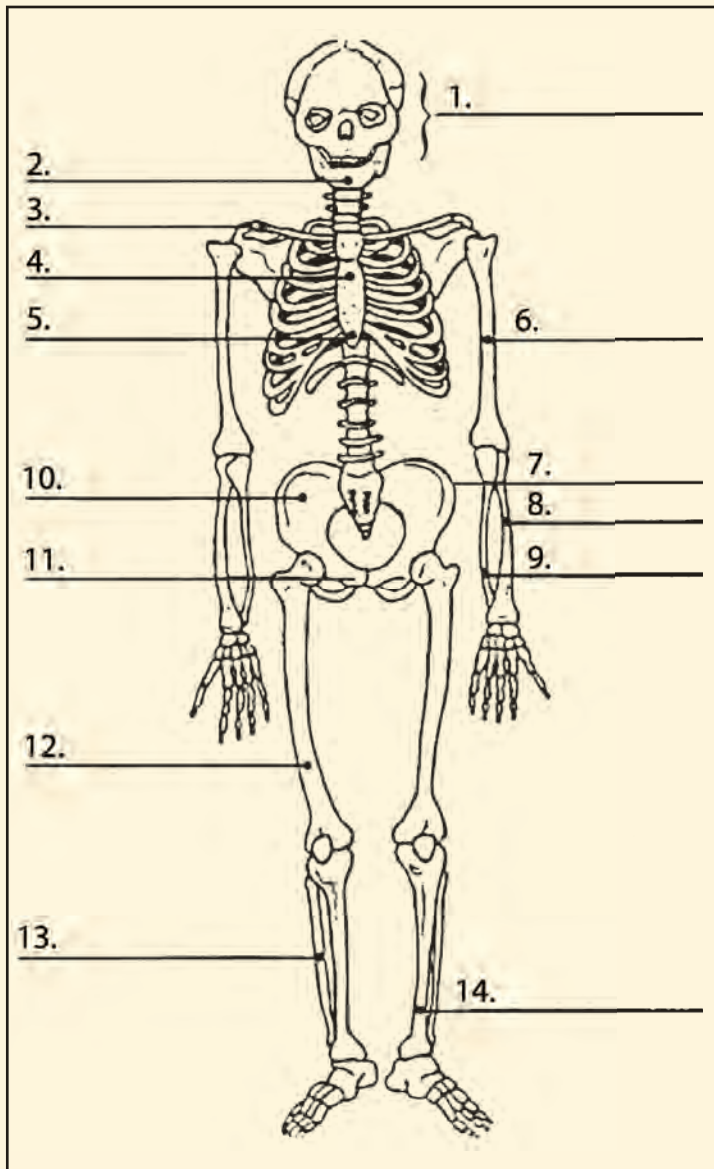


Irregular bone; lumbar vertebra

Identifying Bones

Activity 14.1

Use the library, the Internet, or an anatomy book to identify the following human bones. In your notebook, identify the bones numbered 1–14. Do NOT write in your textbook!



Advance Preparation

Make copies of this skeleton (Blackline Master 14.1) from the Teacher Resource CD to hand out to students for this activity.

Answers

1. skull
2. mandible
3. clavicle
4. sternum
5. xiphoid process
6. humerus
7. iliac crest
8. radius
9. ulna
10. os coxae
11. os pubis
12. femur
13. fibula
14. tibia

Stature: Estimating Height

Forensic scientists can estimate a person's stature (height) by examining one or more of the long bones. The long bones you will consider here are the **femur**, **tibia**, **humerus**, and **radius**. Men and women have different proportions of long bones to total height, so separate formulas have been developed for each. If complete long bones are available, the following formulas may be used to estimate height within a range of ± 7.5 centimeters:

femur: long bone found in the leg extending from the hip to the knee

tibia: long bone found in the leg extending from the knee to the ankle

humerus: long bone found in the arm extending from the shoulder to the elbow

radius: long bone found in the arm extending from the elbow to the wrist

Estimated height of a female (centimeters):

$$H = \text{femur length} \times 2.21 + 61.41$$

$$H = \text{tibia length} \times 2.53 + 72.57$$

$$H = \text{humerus length} \times 3.14 + 64.97$$

$$H = \text{radius length} \times 3.87 + 73.50$$

Estimated height of a male (centimeters):

$$H = \text{femur length} \times 2.23 + 69.08$$

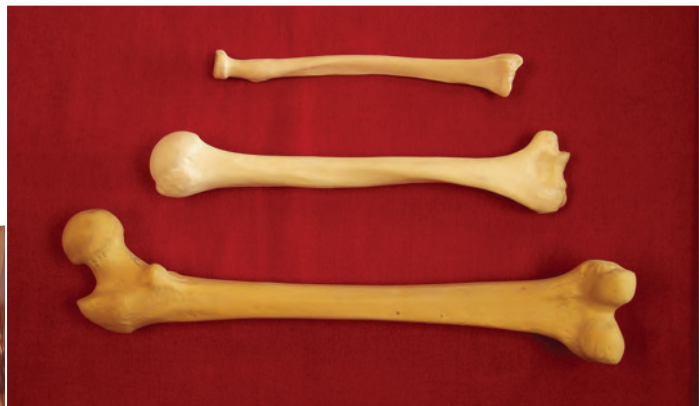$$H = \text{tibia length} \times 2.39 + 81.68$$

$$H = \text{humerus length} \times 2.97 + 73.57$$

$$H = \text{radius length} \times 3.65 + 80.40$$



Measuring the length of a femur to determine height



From top: radius, humerus, femur

Using the equations on page 416, calculate the following long bone lengths and heights. Show all of your work, measurements, and calculations. Remember that 2.5 cm = 1 inch. Be sure to include a range of ± 7.5 centimeters.

1. One of the male skeletons found in Gorman that you read about at the beginning of the chapter had a humerus 34.9 cm long. Approximately how tall would that person have been?
2. The body found in the sewer system that you read about in the beginning of the chapter was found to have a tibia 34.8 cm in length. What would the approximate height be if the body were female? If it were male?
3. Using your own height (in centimeters), what would you expect the length of your femur to be?
4. If you have a skeleton for observation in your class, measure one of its long bones. Calculate the height for a male.
5. Measure two more of the bones on the skeleton. Calculate the approximate height, assuming the skeleton is male.
6. Using the same bones from question 5, calculate the approximate height, assuming the skeleton is female.
7. Measure the height of the skeleton. Based on these measurements, would you assume the skeleton is male or female?

Answers

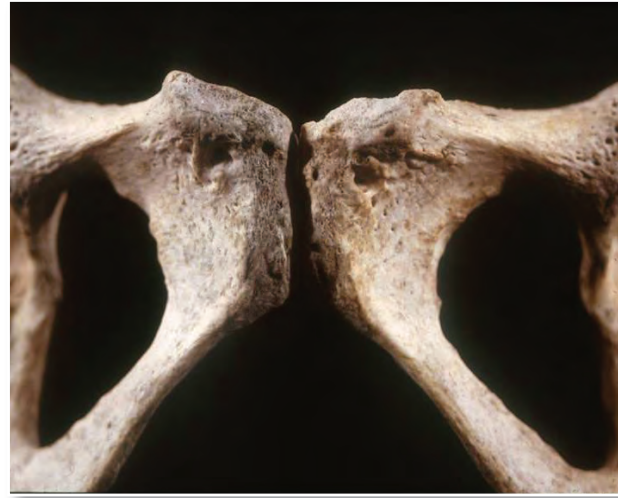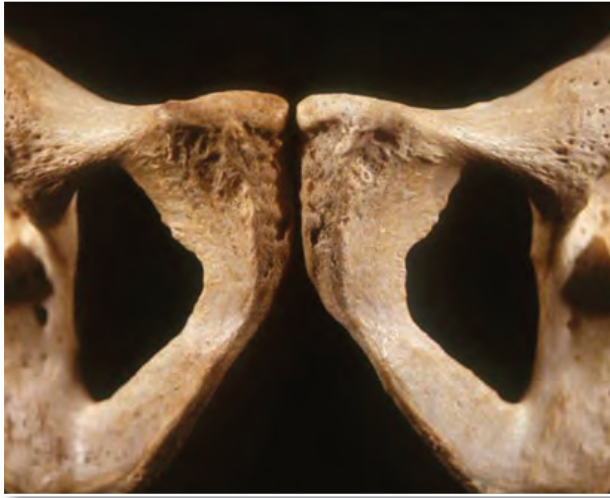1. $34.9 \times 2.97 + 73.57 = 177.22 \pm 7.5$ cm
2. Female: $34.8 \times 2.53 + 72.57 = 160.61 \pm 7.5$ cm
Male: $34.8 \times 2.39 + 81.68 = 164.87 \pm 7.5$ cm
3. Lengths will vary depending on height and whether the student is male or female.
4. Students may choose one of the long bones on the skeleton to measure. Use the equations for male stature.
5. Measure any two of the long bones on the skeleton. Use the equations for male stature.
6. Use the same measurements as in question 5, but calculate the height using the female equations.
7. Answers will vary, depending on the height of the skeleton. If no skeleton is available, perhaps students can use the bone length and height of the teacher!

Sex Determination

Determining sex is crucial when analyzing unidentified human remains. The **os pubis**, sacrum, and ilium of the pelvis are bones that have the most obvious differences between men and women, along with the shape of the skull, the shape of the mandible (jaw), and the size of the occipital protuberance (bump) at the back of the skull. A common way to determine sex is by observing the size of the bones; males tend to have larger bones than females. Males also tend to have larger areas for muscle attachment. The sacrum is straighter in females and more curved in males. The space in the middle of the pelvic bone is larger in women to make birthing easier.

os pubis: area on the anterior side of the pelvis where the hip bones come together

For a more accurate determination, a forensic anthropologist can remove the os pubis from the front of the pelvis and examine it for typically male or female qualities.



Male and female pelvic bones: note the differences

ventral arc: a bony ridge that is formed on the ventral (lower) side of the female os pubis

A forensic anthropologist can make the surest determination of sex by comparing three basic characteristics of the os pubis: the width of the pubic arch, the width of the pubic body, and the existence of a well-defined **ventral arc**, a bony ridge on the lower side of the female pubic bone (see Figure 14.1).

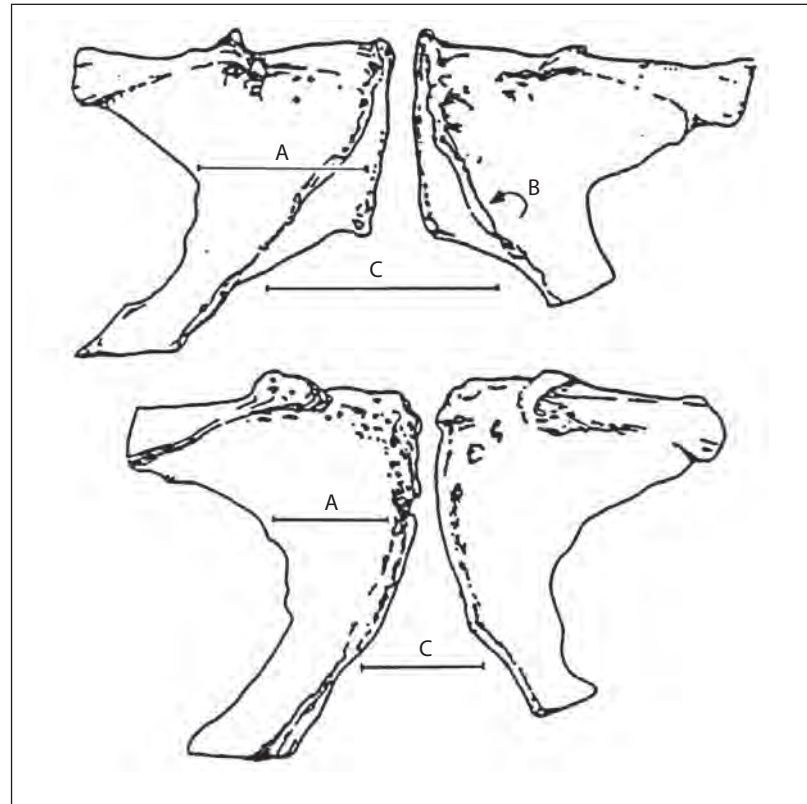


Figure 14.1 Front view of the classic female pubic bones (top), compared with the classic male (bottom). Note the difference in the pubic arch (C) and in the pubic body (A), and the presence of a ventral arc (B) in the female.

The pubic arch has a larger angle in the female than in the male. The pubic body is narrower in males than in females. Males do not usually have a ventral arc.

The ventral arc is a bony ridge found on the bottom side of the pubic bone that does not usually appear in its easily recognizable form until a woman is in her mid-20s. A precursor arc, a small bony line, first appears around the age of 14 (see Figure 14.2).

The ventral arc of a female in her 20s usually resembles that shown in Figure 14.3; the arc is clearly defined, but does not show as heavy a ridge as that seen in older females. Four percent of the female population does not show any ventral arc; when this is the case, the investigator must determine sex through other characteristics.

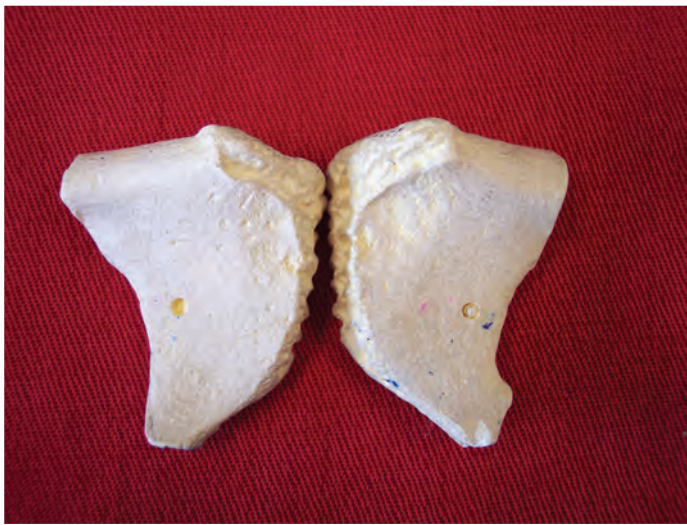

Figure 14.2 Pubic bone of a young adolescent female showing a precursor ventral arc

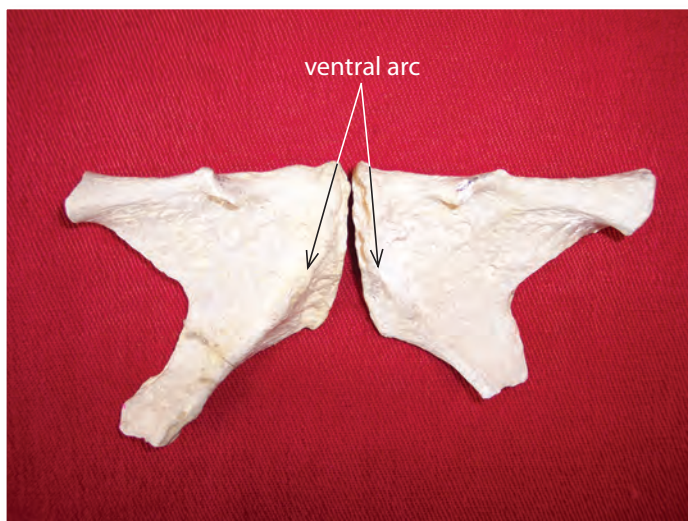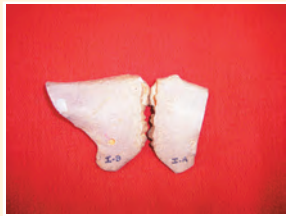


Figure 14.3 Classic female pubic bone, showing the ventral arc

Advance Preparation

These images can be found on Blackline Master 14.2 on the Teacher Resource CD if you want to make copies and hand them out to your students.

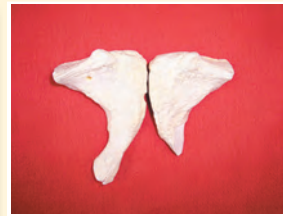Find the os pubis bones on the skeleton in your classroom. Determine which is the dorsal (upper) side and which is the ventral (under) side. Examine the nine sets of os pubis bones pictured below.



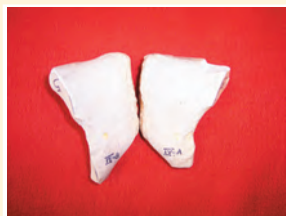female



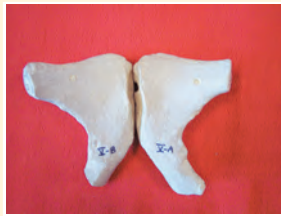female



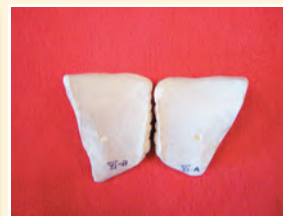male



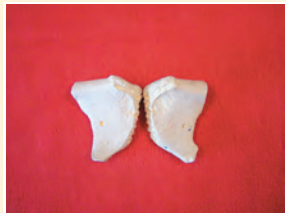male



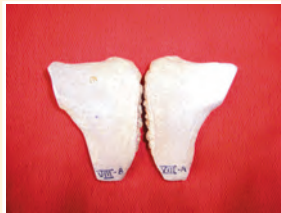male



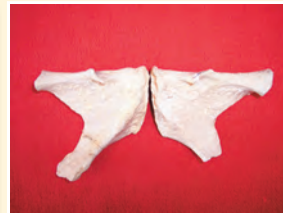female



female



male



female

Procedure

1. Diagram and label each set of bones in your notebook or use the handout provided.
2. Determine the sex of each pair. Clearly state and indicate on the diagram all criteria that apply to each of your decisions.
3. For female specimens, label the ventral arc, if present.
4. Determine the sex of the skeleton provided for your class's observation based on the os pubis.

Differences in Skull Features

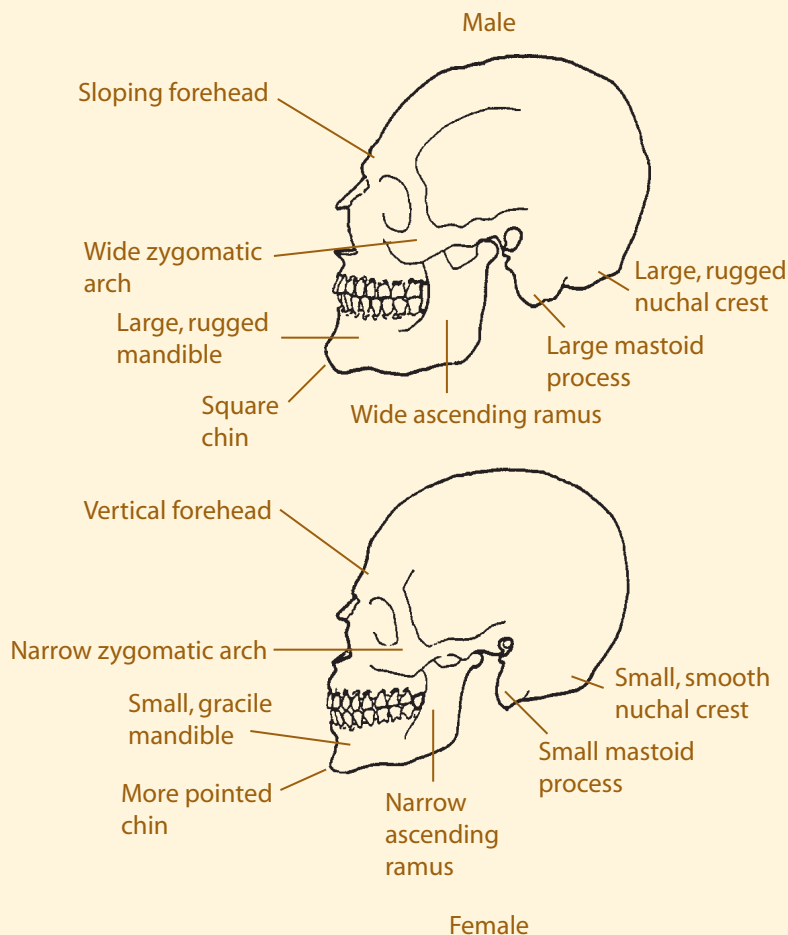
There are several differences between men and women in the sizes and shapes of the bones of the skull, as shown in Figure 14.4.

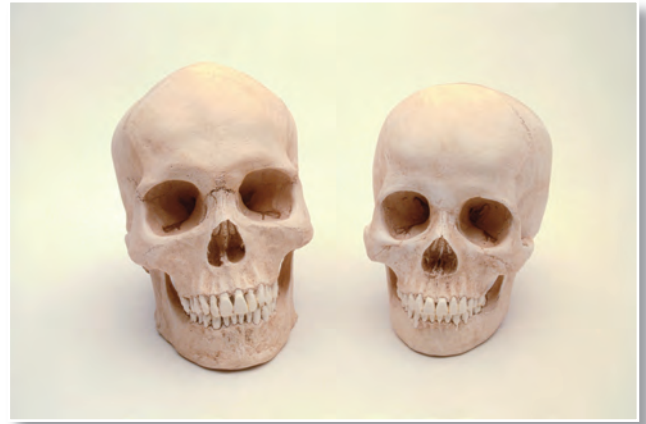

Figure 14.4 Male and female skulls

Determining Sex Using Skull Features

Look at the two skull diagrams below, noting the differences. Circle the differences on the handout and use an anatomy textbook to name the points circled. Determine the sex of the skeleton provided for class observation based on skull features.



Activity 14.3

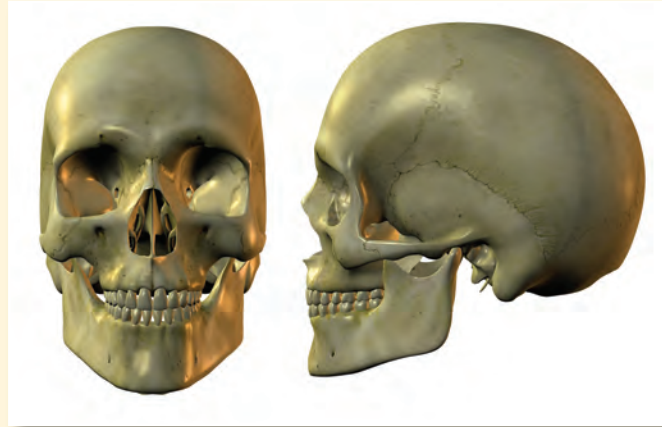
Advance Preparation

Copy Blackline Master 14.3 for your students from the TRCD.

Activity 14.4, *continued*

Answer

The skull is female; note the pointed chin, small mastoid process, and vertical forehead.



Is this a male or female skull?

Determining Age

A forensic anthropologist can reasonably estimate an individual's age at the time of death by examining biological changes that took place during that person's life. The investigator can estimate most accurately when teeth are erupting, bones are growing, and **epiphyses**, or growth plates, are forming and uniting. Closure of cranial sutures in the skull is also an age indicator. After this growth period, at around 25 to 30 years old, age estimation becomes more difficult and depends on the degenerative changes in the skeleton.

epiphyses: growth plates found at the ends of the long bones. They form in adolescence and fuse to the bone during early adulthood.

diaphysis: the shaft of a long bone

iliac crest: found on the top of the hip bone

Skeletal changes happen at different ages in different individuals. All estimates are just that: estimates. The forensic anthropologist always gives the investigators an age range to avoid excluding any possibilities in identifying unknown remains. Looking at multiple sites or multiple age indicators can narrow the range of the estimate.

The **diaphysis**, or shaft, makes up most of a long bone's length. Epiphyses are found at both ends of the long bone; their function is to allow for growth. The epiphyses are good places to look for changes in estimating age. Though all people are different and grow at different rates, there are similarities that make generalizations possible in estimating age.

The epiphyses fuse to the bone during adolescence and can be examined in four stages:

Stage 1: Nonunion with no epiphysis (there is no growth plate yet).

Stage 2: Nonunion with separate epiphysis (the growth plate is formed but not attached).

Stage 3: Partial union of the epiphysis (growth plate is beginning to attach to the bone).

Stage 4: Complete union of the epiphysis (growth plate is completely attached and smooth).

These stages happen at different ages in different bones and also differ between males and females, as shown in Tables 14.1 and 14.2. A photo of the **iliac crest** is shown in Figure 14.5.



Figure 14.5 Photograph showing stage 1 of the iliac crest. Notice the line where the growth plate on top is attached, yet not completely smoothed over.



Femur showing partial union of growth plates at each end. Stage 3.

Table 14.1: General Age Determinations Using Epiphyseal Union of the Medial Clavicle

| Stage of Union | Male | Female |
|-------------------------------------|---------------|---------------|
| Nonunion without separate epiphysis | 21 or younger | 20 or younger |
| Nonunion with separate epiphysis | 16–21 | 17–20 |
| Partial union | 17–30 | 17–33 |
| Complete union | 21 or older | 20 or older |

Table 14.2: General Age Determinations Using Epiphyseal Union of the Iliac Crest

| Stage of Union | Male | Female |
|-------------------------------------|---------------|---------------|
| Nonunion without separate epiphysis | 16 or younger | 11 or younger |
| Nonunion with separate epiphysis | 13–19 | 14–15 |
| Partial union | 14–23 | 14–23 |
| Complete union | 17 or older | 18 or older |

clavicle: also known as the collarbone; its medial ends meet in the center of the body

Advance Preparation

Number 4 is included on the Teacher Resource CD as Blackline Master 14.4 in case you want to create a handout for your students.

Answers

- 2 and 3.** Ci: stage 1 male 21 or younger
female 20 or younger
Cii: stage 2 male 16-21
female 17-20
Ciii: stage 3 male 17-30
female 17-33
Civ: stage 3 male 17-30
female 17-33
Cv: stage 4 male 21 or older
female 20 or older
- 4.** Answers will vary depending on the skeleton used in the classroom.
- 6.** li: stage 1
lii: stage 2
liii: stage 3
liv: stage 3
lv: stage 3
lvi: stage 4
lvii: stage 4

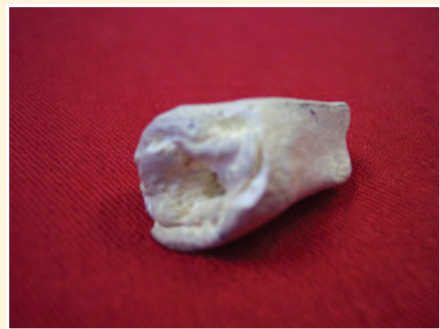1. Study the medial **clavicle** samples in the photos below (Ci through Cv) and note the differences in the surfaces. How does the epiphyseal surface change with age? Diagram and record your observations or use the handout.
2. Label the stage of epiphyseal union in each sample.
3. Using Table 14.1, determine the approximate age of each specimen.
4. Determine the age of the model skeleton based on the various epiphyses.



Ci



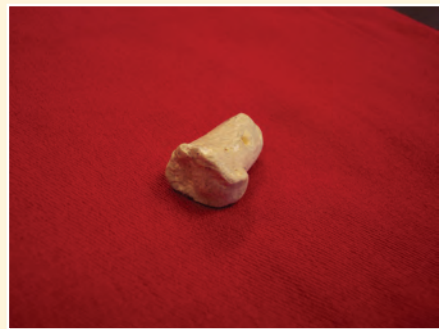Cii



Ciii



Civ



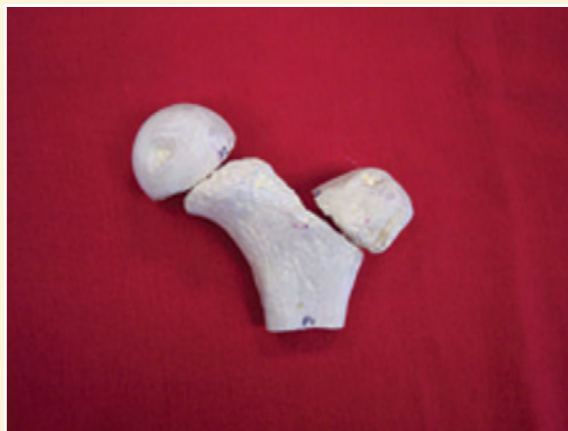Cv

Forensic anthropologists can also use the epiphyseal union of the anterior (front side) iliac crest as an indicator of age. The iliac crest is found on the hip bone. Locate the iliac crest on the skeleton. The four stages of union are the same as for the medial clavicle, though the age range is different.

5. Study the samples in the photo below (Ii through Ivii) and note the differences in the surfaces. How does the epiphyseal surface change with age? Diagram and record your observations or use the handout.
6. Label the stage of epiphyseal union in each iliac crest sample in the photo.



7. Use Table 14.2 to determine the approximate age of each specimen in the photo.
8. Samples F1, F2, and F3 in the photo at right are parts of the femur. These epiphyses begin to unite between the ages of 14 and 19 in males. Where is the femur found on the skeleton?
9. What is the approximate age of the specimen in the photo?



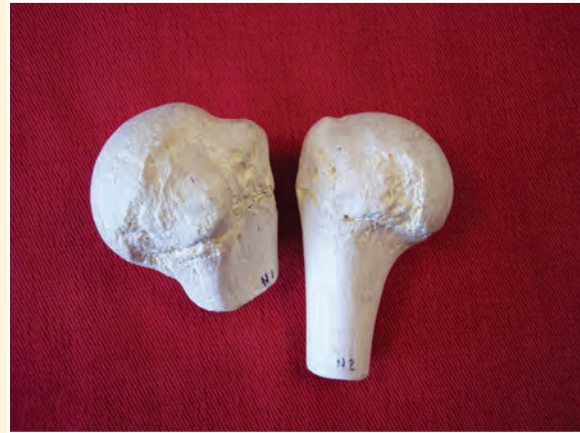7. Ii: stage 1 male 16 or younger
female 11 or younger
Iii: stage 2 male 13-19
female 14-15
Ivii: stage 2 male 13-19
female 14-15
Iv: stage 3 male 14-23
female 14-23
Ivi: stage 3 male 14-23
female 14-23
Iv: stage 3 male 14-23
female 14-23
Ivi: stage 4 male 17 or older
female 18 or older
8. It is the upper leg bone.
9. They are in stage 2, so the specimen must be under 14.

Answers, continued

- 10. It is one of the arm bones.
- 11. They are in stage 3.

Activity 14.4, continued

- 10. Samples H1 and H2 in the photo at right are parts of the humerus. Where is the humerus found?
- 11. What are the stages of epiphyseal union in these two fragments?



Estimating Age Based on Cranial Sutures

Additional important age indicators are the **sutures** located on the skull. The bones of the skull come together or unite along special serrated and interlocking joints known as sutures. The sutures allow for growth of the skull.

sutures: immovable joints where bones are joined together. They are visible as seams on the surface.

The *sagittal suture* is located along the top of the skull, dividing right from left, and runs from the top of the

skull to the middle of the back of the skull. Locate the sagittal suture on the skeleton.

The *coronal suture* runs from the temporal area on one side over the top of the skull to the other side. Locate the coronal suture on the skull. The *lambdoidal suture* is located on the back of the skull. Find this suture on the skull.

If the sagittal suture is completely closed (not visible at any point):

Male: The individual is 26 years of age or older.

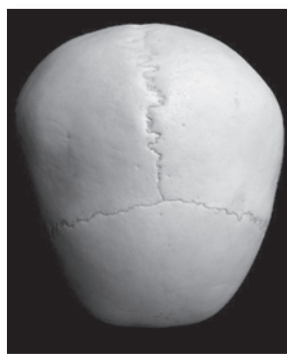
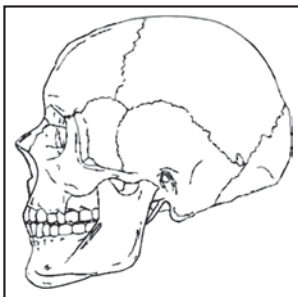
Female: The individual is 29 years of age or older.

If the sagittal suture is completely open (visible at all points):

Male: The individual is younger than 32 years old.

Female: The individual is younger than 35 years old.

Looking at these two criteria together, it could be said that the sagittal suture is not likely to be open if a male is older than 32 and not likely to be closed if he is younger than 26. For a female, the suture is not likely to be open after 29 and not likely to be closed if younger than 35 years old.



Human skull showing sagittal and coronal sutures

If the skull shows complete closure of all three major sutures (no visible suture lines):

Male: The individual is older than 35.

Female: The individual is older than 50.

Determine the age of the model skeleton based on cranial sutures.

Teacher Note

Answers will vary depending on the features of the skeleton used in class.

Determining Age Using the Os Pubis

Examining the closing of the epiphyses is a good method to determine age in younger skeletal remains. Once the epiphyses are closed, forensic anthropologists observe degenerative changes to determine age. One of the best areas to determine age in an adult is from the pubic **symphysis**, which is the area where the two hip bones come together in front. As a person ages, the two bones may rub together, producing changes or wear patterns.

symphysis: a place where two bones meet and may rub together

The symphyseal face of the pubic bone undergoes a regular metamorphosis, or change, from puberty onward. Basically, the pattern on the symphysis goes from being in regular rows or furrows in younger individuals, to smooth with an oval surface, to a breakdown of the bone in older individuals.

14.1: Massacre at El Mozote

Between 1980 and 1991, the Republic of El Salvador in Central America was engulfed in a vicious civil war that left thousands dead. A particularly violent episode in December of 1981 involved the destruction of the village of El Mozote and the killing of all but a few of its inhabitants by U.S.-trained government troops. Forensic examination of one structure, a church building, found the remains of the village's children. The government had claimed that everyone was killed as a result of combat between troops and the guerillas.

Over ten years later, forensic anthropology and firearms identification proved that the 150 or so children were executed by being gunned down within the small building, which was subsequently burned.

CASE STUDY



Examining and sorting bones from the church building

The conclusions were:

- All the skeletons were deposited at the same time.
- From an examination of coins and cartridge cases, it was determined that the event occurred no later than 1981.
- Most victims were under the age of 12; the average age was six years old. There were also five adolescents and seven adults, one a pregnant woman.
- Most of the skeletons were associated with bullet fragments, many in parts of the body in which a bullet wound would have caused death.
- Wound paths and pock marks in the floor indicated that some victims were shot while lying in a horizontal position on the floor.
- Though there were many entrance wounds in the skulls, very few showed exit wounds, indicating that the ammunition was of the type likely to fragment upon impact.
- The large number of cartridge cases and bullets found allowed for statistical analysis as to the type of weapons employed, the minimum number of shooters, and the firing areas.
- From that statistical analysis, it was determined that the ammunition was manufactured in the United States; practically all the weapons were U.S. M-16 military rifles such as those issued to Salvadoran government troops in the war.

**CASE STUDY
CONTINUED**

—condensed from *The Missing: Human Remains*
at www.icrc.org/themissi.nsf

This case shows how much information can be gained by the detailed investigation of evidence, even after many years. A combination of forensic anthropology and firearms examination allowed the development of a complete picture of the awful event, thereby refuting government claims.

Determination of Race

There are three major anthropological racial groups based on observable skeletal features: Caucasoid, which includes people of European, Middle Eastern, and East Indian descent; Negroid, which includes people of African, Aborigine, and Melanesian descent; and Mongoloid, which includes people of Asian, Native American, and Polynesian descent. In most areas of the world, populations have mixed, blurring the distinctions among the races. It is important to note that there is more individual variation within races than there is general variation among races. The major differences can be best seen in the skull features.

Caucasoids have a long, narrow nasal aperture, a triangular palate, oval orbits, narrow zygomatic arches, and narrow mandibles.

Negroids have a wide nasal aperture, a rectangular palate, square orbits, and more pronounced zygomatic arches. The long bones are longer and have less curvature and a greater density.

Mongoloids have a more rounded nasal aperture, a parabolic palate, rounded orbits, wide zygomatic arches, and more pointed mandibles.

Caucasoid: descriptor for people of European, Middle Eastern, and East Indian descent

Negroid: descriptor for people of African, Aborigine, and Melanesian descent

Mongoloid: descriptor for people of Asian, Native American, and Polynesian descent

Note and compare the differences in the skull features in Figures 14.6, 14.7, and 14.8.

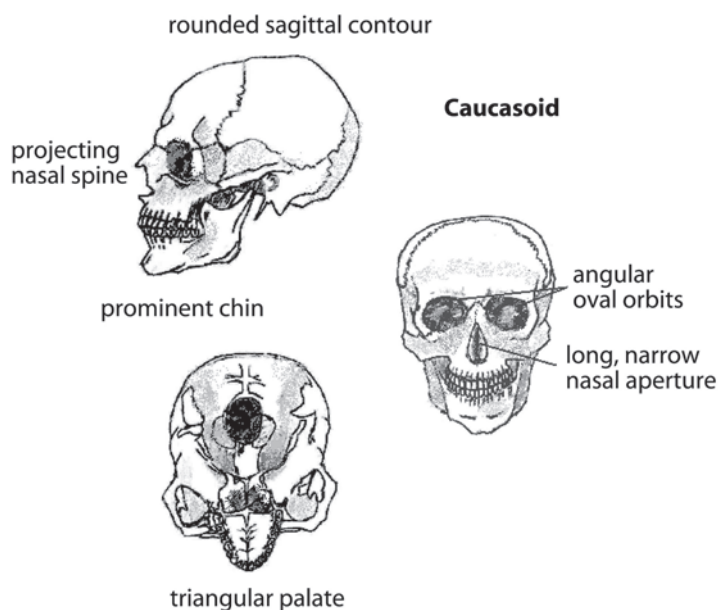


Figure 14.6 Caucasoid skull

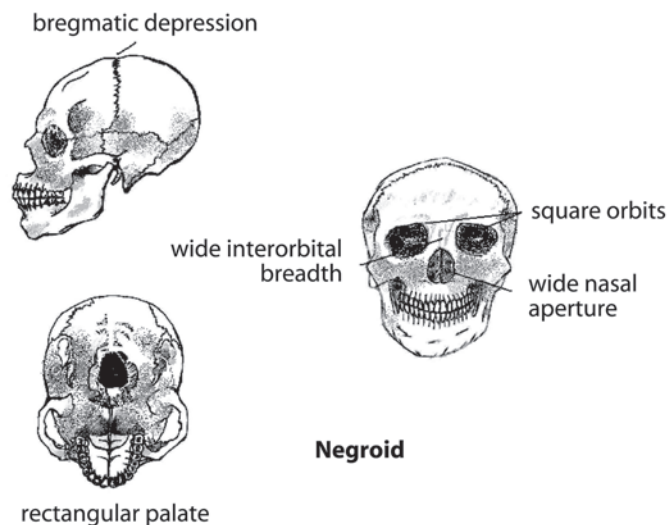


Figure 14.7 Negroid skull

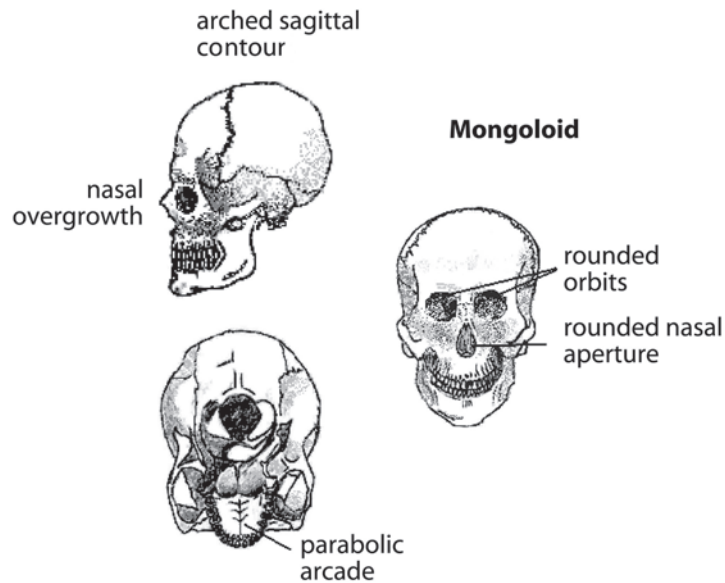


Figure 14.8 Mongoloid skull

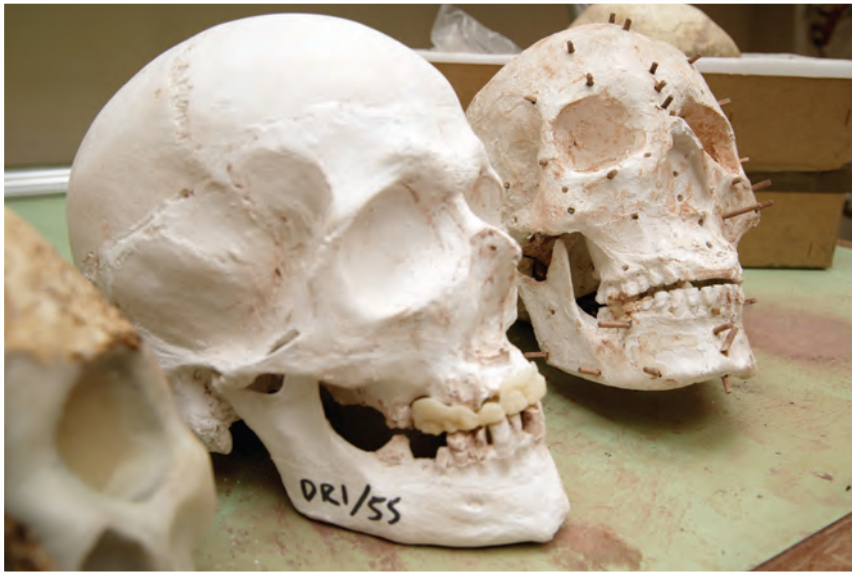Facial Reconstruction

There are 21 landmarks, or positions on the skull, placed at particular points where the tissue thickness has been determined from empirical data. Markers are glued to these landmarks so that clay can be added later to form the face.

When unidentified remains cannot be connected to any particular missing person and traditional methods of identification have failed, facial reconstruction may be important. Facial reconstruction uses standard tissue thickness and facial muscles to build a new face on a skull. The information from the skull and skeleton gives gender, age, and race. The artist then uses data that have been collected about tissue depth in the different races, ages, and genders to build a new face on the skull. This technique is not completely accurate, but it has proven to be highly successful in forensic cases, helping to identify unknown persons.

Steps in facial reconstruction include:

1. Establish gender, age, and, if possible, race.
2. Glue tissue markers to landmarks directly on the skull for tissue thickness.
3. Mark muscle insertion points.



The facial reconstruction process begins by placing the 21 landmarks

4. Select a data set to use for the particular skull, and mount markers for the exact thickness of tissue.
5. Mount eyes in the sockets, centered and at the proper depth.
6. Apply clay to the skull, following its contours and using the depth of the tissue markers and muscle insertion points.
7. Make measurements to determine the nose thickness and length and the mouth thickness and width.
8. Cover the skull with layers of skin and add details of the face.



Adding clay features to the skull



The finished reconstruction

The person reconstructing the skull may add a wig, glasses, earrings, or clothing to better accentuate the features of the individual. To add personal touches, the reconstructor relies on information from the forensic anthropologist and investigators for lifestyle, profession, and geographic location of the deceased.

After the reconstruction is complete, photographs are distributed to help in the identification of the individual. Sometimes skull-photo superimpositions are useful when possible individuals are identified. In this method, the reconstructor lays a photo of the individual over the photo of the facial reconstruction, using a computer program to see if the features or structures match.

Accuracy is not the most important factor for a recognizable reconstruction. Proportion is much more important; the positioning of the facial features such as mouth, nose, and eyes in relation to each other is most helpful in recognition. Studies have shown that the brain picks up on the *differences* when a photo and reconstruction are seen together, but *similarities* when each is viewed alone. The whole point of facial reconstruction is to provide an image that may spark some recognition when viewed by the right person. Archeological reconstruction of ancient bones uses similar techniques, but without anything to compare with the reconstruction, there is no way to determine accuracy.



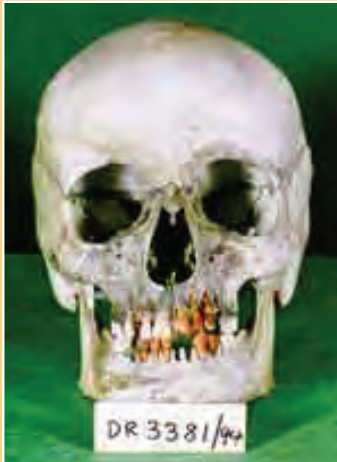Scientist works on reconstructing the skull to find the identity of an unknown individual

14.2: Facial Reconstruction

CASE STUDY

In 1994, a tourist found the skeleton of a young Caucasian female near the summit of Table Mountain in Cape Town, South Africa. By a remarkable coincidence, a newspaper reporter present when the remains were discovered had covered the disappearance of a young woman suffering from chronic depression six years earlier. Two empty blister packs of sleeping pills, a lethal dose, had been found with the remains. This find led to the deceased's parents. In order to confirm the missing woman's identification, the skull and mandible were used to reconstruct the face of the young woman, without reference to a photograph of her. The parents of the deceased viewed the facial reconstruction and confirmed that the resemblance to their daughter was sufficient to confirm her death.

—condensed from a 2001 FBI report,
www.fbi.gov/hq/lab/fsc/backissu/jan2001/phillips.htm



The skull found on Table Mountain



The sculptured face in modeling clay on a plaster model of the skull



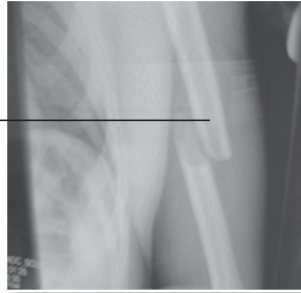A photograph supplied by the parents at the time of the disappearance of their daughter

Note how coincidence and discovery of evidence allowed the manner of death to be discovered, which led to identification of the cause of death (see page 376, Chapter 13).

The Cause of Death and Bone Anomalies

The cause of death is usually left to the pathologist to determine, but if only skeletal remains are left, an anthropologist may be consulted. Sometimes the cause of death is obvious, leaving its mark on the skeleton; stab wounds, bullet holes, and blows to the head may leave a unique

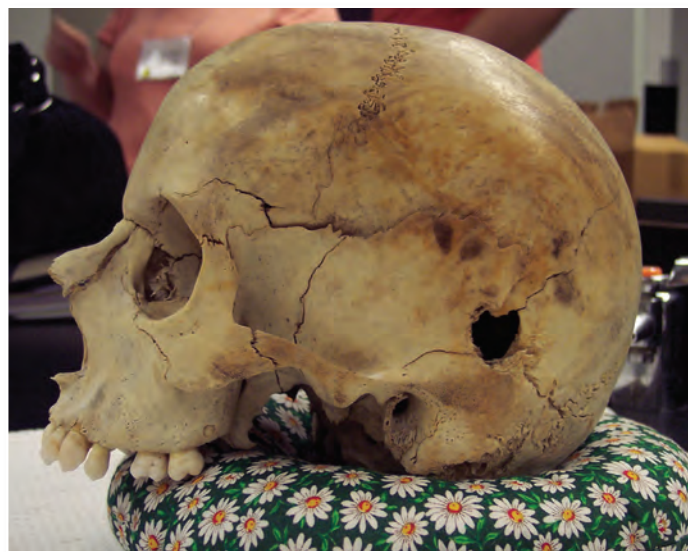signature. Sometimes the murder weapon has left a distinctive mark that can be matched to a wound on the skull. The investigator must be careful to be sure that any markings are a result of the crime and did not occur after death. Bones that have been found outside often have scavenger marks left by animals.



X ray of a broken humerus

Bones may also show earlier injuries such as healed breaks or fractures. People who have had joint replacements may be identified by the particular replacement, maybe through a serial number or from an X ray. Forensic anthropologists can also see bone diseases such as osteoporosis, arthritis, or rickets; these will help in identification.

Forensic anthropology uses the knowledge and techniques of osteology, archeology, pathology, art, and crime investigation to give voice to the dead. It is applied in the identification of unknown remains—both modern and ancient—of victims of crimes, mass disasters, and natural or unknown causes.



Bullet hole in a skull showing cause of death. Note the sutures and growth plates for indicators of age.

Checkpoint Questions

Answer the following questions. Keep the answers in your notebook, to be turned in to your teacher at the end of the unit.

1. What do anthropologists study?
2. What can skeletal remains reveal about the identity of a person?
3. How are animal bones different from human bones?
4. What is the difference between tendons and ligaments?
5. What are the functions of the skeleton?
6. Explain how the height of an individual can be estimated from the skeleton.
7. Which bones best indicate gender?
8. Using the bones from question 7, give the differences between male and female.
9. What are the four stages of epiphyseal union?
10. What is the function of cranial sutures?
11. When are the cranial sutures completely closed?
12. Explain how the symphyseal face on the os pubis changes as a person ages.

Answers

1. They study human anatomy, variability, evolution, and culture.
2. whether the remains are human, age, sex, race, when death occurred, sometimes cause of death, approximation of height, anomalies, diseases
3. They are different in size and shape. Microscopic examination shows that in animals the osteons form a regular pattern, but in humans the osteons are arranged in a more chaotic pattern.
4. Tendons connect muscle to bone; ligaments connect bone to bone.
5. It provides structure and rigidity, protects soft tissue and internal organs, provides sites for muscle attachment, allows for movement, stores minerals, and houses sites that produce red blood cells.
6. The height can be estimated if one or more of the long bones are present. Mathematical equations can be used to determine male or female height, knowing the length of a particular long bone.
7. the os pubis, skull features, sometimes length of long bones
8. Using the os pubis, the subpubic angle is larger in females, the pubic body is wider in females, and females have a ventral arc. In the skull, the male has a more square chin, a wider zygomatic arch, a larger mastoid process, and a larger mandible than the female.

The long bones in males are generally longer and more dense.
9. (1) no growth plate; (2) growth plate exists but is not attached; (3) growth plate is attached but still identifiable; (4) growth plate is attached and smoothed over
10. to allow for growth of the skull
11. in males after age 35; in females after age 50
12. The symphyseal face first rubs together and smooths as a person ages, then later in life begins to break down.

Answers, continued

13. Negroid has a wide nasal aperture; Caucasoid has a long and narrow nasal aperture; Mongoloid has a rounded nasal aperture. Negroid has a rectangular palate; Caucasoid has a triangular palate; Mongoloid has a parabolic palate. Negroid has square orbits; Caucasoid has angular, oval orbits; Mongoloid has rounded orbits. Other differences can be seen on pages 429–430.
14. Tissue markers are glued to landmarks directly on the skull for tissue thickness; muscle insertion points are marked; eyes are mounted in the sockets, centered and at the proper depth; clay is applied to the skull, following the contours of the skull; various measurements are made to determine the nose thickness and length and the mouth thickness and width; the skull is covered with layers of skin; and details of the face are added.
15. bullet holes, cracked skull showing blunt force trauma, stabbing or cutting wounds that cut to the bone
16. no intervening layers of material; same amount of weathering and aging; no more recent artifacts associated with death
17. Epiphyseal union of iliac crest would have been the most accurate method for ages under 17–18.
18. Cause of death = what caused death: Blunt trauma? Gunshot wound to head? Heart disease? etc. Manner of death = how it happened?: Five categories—homicide, suicide, natural, accidental, undetermined.

Optional Website Activity

Have students conduct the virtual autopsy case that can be found in the Chapter 14 student resources area (SCSI tab) on the *Forensics* website. See the teacher resource section on the site for more information.

13. Name three differences in the skull shapes of the three anthropological racial groups.
14. Briefly explain how a forensic anthropologist may reconstruct a face on a skull.
15. Give a few examples of how skeletal remains may show the cause of death.
16. In the El Mozote Case Study, all the skeletons were deposited at the same time. How would that have been determined?
17. How would the age of victims have been estimated?
18. What is the difference between cause of death and manner of death?

References

Books and Articles

- Bass, W. *Human Osteology: A Laboratory and Field Manual*. Columbia: Missouri Archeological Society, 1996.
- Jackson, D. *The Bone Detectives*. New York: Little, Brown and Company, 1996.
- Kurland, M. *How to Solve a Murder*. New York: Macmillan, 1995.
- Maples, W., and M. Browning. *Dead Men Do Tell Tales: The Strange and Fascinating Cases of a Forensic Anthropologist*. New York: Broadway Books, 2001.
- Osterburg, J. *Criminal Investigation: A Method for Reconstructing the Past*. Cincinnati: Anderson Publishing Co., 1992.
- Owsley, D. "Fragments of Murder," *Chem Matters*, April 1996, pp. 12–15.
- Saferstein, R. *Criminalistics: An Introduction to Forensic Science* (7th ed.). Upper Saddle River, NJ: Prentice Hall, 2001.
- Saladin, K. *Anatomy and Physiology: The Unity of Form and Function*. Boston: McGraw-Hill, 2001.
- Shier, D., J. Butler, and R. Lewis. *Hole's Essentials of Human Anatomy and Physiology*. Boston: McGraw-Hill, 2000.
- Suchey, J. M., and S. Brooks. "Skeletal Age Determination Based on the Os Pubis," *Human Evolution Journal*, vol. 5 (1990), pp. 227–238.
- Suchey, J. M., and P. A. Owings Webb. "Epiphyseal Union of the Anterior Iliac Crest and Medial

Clavicle," *American Journal of Physical Anthropology*, vol. 68 (1985), pp. 457–466.

Suchey, J. M., and L. D. Sutherland. "Use of the Ventral Arc in Pubic Sex Determination," *Journal of Forensic Sciences*, vol. 36, no. 2 (March 1991), pp. 346–355.

Ubelaker, D., and H. Scammell. *Bones: A Forensic Detective's Casebook*. New York: Edward Burlingame Books, 1992.

Websites

www.forensicartist.com; nice set of reconstructions, from skull to finished product

www.pbs.org/opb/historydetectives/techniques/forensic_ml.html; links

<http://library.med.utah.edu/kw/osteo/forensics/index.html>; overview of forensic anthropology with links to cases

www.crimelibrary.com/criminal_mind/forensics/anthropology/1.html; case history

Other

Cast sets of os pubis bones for sex identification, epiphyseal age determination, and forensic applications are available from:

Diane France
20102 Buckhorn Road
Bellvue, CO 80512